

# Gene Expression of Tumor Suppressor Protein (p53 gene) and Histopathological Study of Tonsillitis Tissue

Nuha SH. Ali<sup>1</sup>, Zainab I. Mohammed<sup>2</sup>

<sup>1</sup>Department of Basic Sciences, College of Dentistry, University of Al-Qadisiyah, Diwaniyah, Iraq.

<sup>2</sup>Department of Physiology, Biochemistry, and Pharmacology, College of Veterinary Medicine, University of Al-Qadisiyah, Diwaniyah, Iraq.

## Abstract

The goal of the current investigational research was focused on explaining the role of tumor suppresser protein (p53) during tonsillitis infection in children by studying the gene expression of the P53 gene in tonsil-tissue cells by a quantitative reverse transcription Real-Time PCR method (RT-qPCR) and histopathological changes of tonsillitis. Here, 20-tonsil biopsy samples were collected from patients with tonsillitis more than 10 years of age in Al-Diwaniyah Teaching Hospital that were subjected to histopathological examination and the RT-qPCR technique for the p53 gene expression analysis (P53GE). The results showed that the P53GE was slightly higher but not significant, 2.5-fold change and  $p>0.05$ , than that in normal tissues. The histopathological changes demonstrated features such as hyperplasia, collagen fiber aggregation, and hypertrophy. In conclusion, there is no activation of the p53 expression levels in the affected tonsils during tonsillitis.

**Keyword:** Gene expression, p53, tonsillitis, tumor suppresser gene.

## INTRODUCTION

When look at the formation of tonsils, groups of lymphoid tissues, partially protruded into the aerodigestive tract, form this organ, and these tissues in combination are called Waldeyer's tonsillar ring that consist of certain tonsil parts of adenoid, 2 tubal, 2 palatine, and the lingual part (1). When the tonsil gets an inflammatory process, then the condition is called tonsillitis usually known as a pharyngitis type. Fever with sore in the throat, tonsil enlargement, annoying swallowing, and sometimes abscesses in the peritonsillar area (2). Viruses are the most important etiological agents that induce tonsillitis (3). Strep throat is a bacterial tonsillitis that is caused by streptococcus bacteria (4). Bacterial tonsillitis caused by *Corynebacterium diphtheria*, *Neisseria gonorrhoeae*, or *Haemophilus influenzae* is rare to occur. Transmission of the infection is happened due to airborne modes. These causes can be separated via a scoring system of the infection; however, Lab tools such as throat swabbing or rapid tests could be useful in confirming the causative agent (5). Every year, 2% of patients (usually occurs in school children during fall and winter) visit the ENT doctors and/or health centers around the world for cases of tonsillitis (3,5,6). Tonsillitis is a self-limited condition that usually doesn't need medication. For the p53 (a conserved gene that is linked to cancer as a 50% loss or mutation in this gene is found), chromosome 17p13.1 is considered as the spot for the presence of this genetic material that encodes for the production of its protein, p53 (7). Low levels of this gene product is present in the cells per normal status of these cells; however, increases in these levels are noticed when these cells are stimulated via DNA-damage-related signals leading via upregulation of this gene to either DNA repair or apoptosis processes that help in defending the human body against malignant cancers (8,9). Sometimes, increases in the levels of the protein encoded by p53 was found to be for increasing stabilization for different proteins, post-translationally, such as heat-shock proteins (10,11). The goal of the current investigational research was focused on explaining the role of tumor suppresser protein (p53)

during tonsillitis infection in children by studying the gene expression of the P53 gene in tonsil-tissue cells by a quantitative reverse transcription Real-Time PCR method (RT-qPCR) and histopathological changes of tonsillitis.

## MATERIALS AND METHODS

### Patient's specimens

Here, 20-tonsil biopsy samples were collected from patients with tonsillitis more than 10 years of age in Al-Diwaniyah Teaching Hospital. These samples were placed in sterile collection tubes with DEPC. Then, the samples were transported to a laboratory and stored in deep freezing.

### Extraction of total RNA

Extraction of the total RNA was made using Accuzol® kit (Bioneer, Korea) and with the relying on its protocol. Briefly, 100mg from each biopsy was used to start the extraction procedure. A NanoDrop (ThermoFisher, USA) was employed to test the quality and the quantity of the total RNA extracted from the extraction process. DNase was used to eliminate the remaining of genomic DNA using DNase I kit (Promega, USA) with relying on the protocol packed with this kit.

### Reverse transcription for cDNA production

The process was generated using AccuPower® RocktScript RT PreMix kit (Bioneer, Korea) following its protocol. The conditions used for the reactions in a thermocycler were 1hour at 50°C to do the cDNA-synthesis process and 5min at 95°C for the heat-inactivation process.

### RT-qPCR

The P53GE quantification was made using the 2<sup>-ΔΔCT</sup> Livak method(12). The RT-PCR system (BioRad, USA) was employed via the use of SYBER Green dye qPCR master mix with relying on the quantification of the β-actin as a housekeeping gene (HKG) for the normalization process. Primers were designed using the primer3 plus web site. These primers are F: ATCCTCACCATCATCACACTGG and R: ACAAACACGCACCTCAAAGC to target a region

at 75bp of the p53 gene (NM\_000546.5) and F: TCGTGCCTGACATTAAGGAG and R: TTGCCAATGGTGATGACCTG to target a region at 133bp of the HKG (NM\_001101.3). The master mixes were produced using AccuPower™ 2XGreen Star qPCR kit (Bioneer, Korea) and relying on the protocol accompanied the kit. The conditions of the thermocycler for the reactions were 1 whole cycle for initial denaturation for 1h at 50°C, 40 cycles for (20s-95°C Denaturation and 30s-60°C Annealing\Extension Detection), and 1 whole cycle for 0.5s at 60 to 95°C for the melting step.

### RESULTS

The results showed that the P53GE was slightly higher but not significant, 2.5-fold change and  $p > 0.05$ , than that in normal tissues, figure 1.

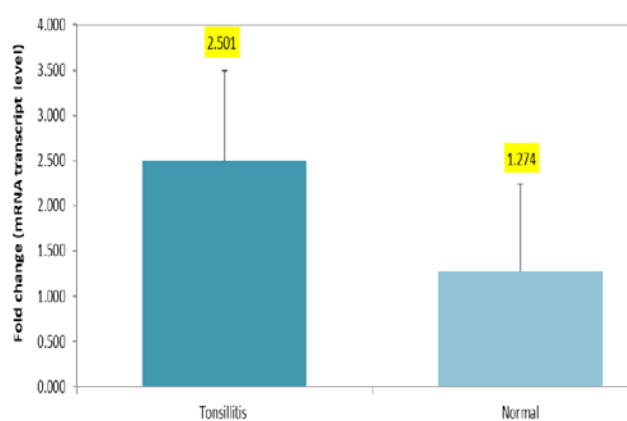
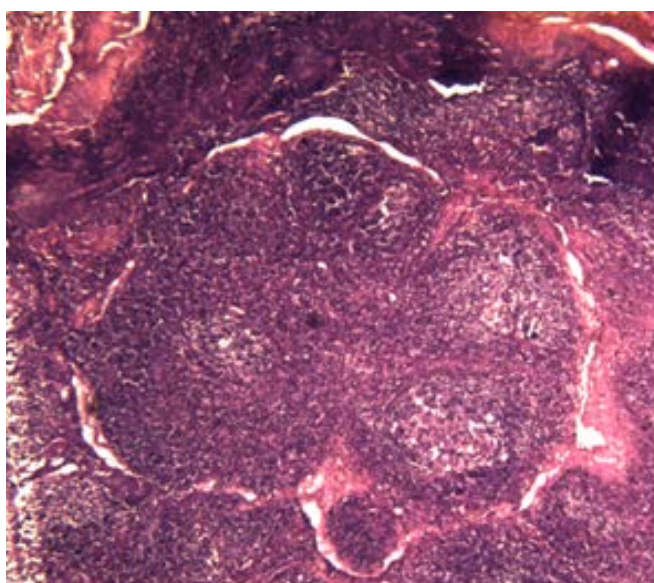
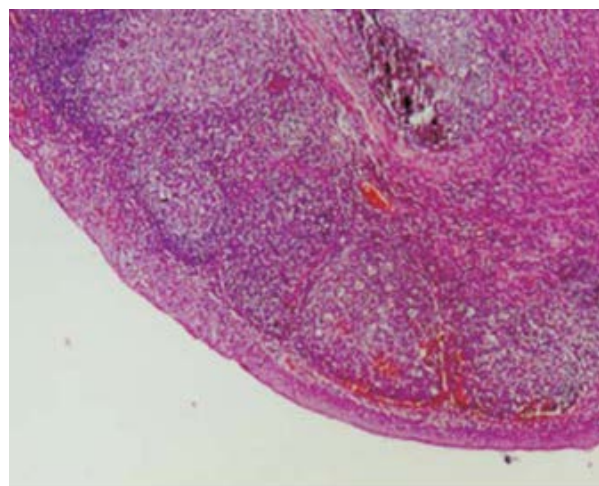


Figure 1: Fold change of the P53GE. There are increases but not significant.

The histopathological changes demonstrated features such as hyperplasia, collagen fiber aggregation, erosions, necrosis, and hypertrophy, figure 2 (A, tonsillitis, and B, normal tonsil).



A



B

Figure 2: A. The histopathological changes in tonsillitis demonstrated features such as hyperplasia, collagen fiber aggregation, erosions, necrosis, and hypertrophy (200X and H&E stain). B. Normal tissues of a tonsil (200X and H&E stain).

### DISCUSSION

The tonsil is considered as an important tissue for immunity generation and protection. At ages of 6 to 7 years old, the tonsils are large in size with acquiring immunity that decreases in size after these ages (13). Low levels of this gene product is present in the cells per normal status of these cells; however, increases in these levels are noticed when these cells are stimulated via DNA-damage-related signals leading via upregulation of this gene to either DNA repair or apoptosis processes that help in defending the human body against malignant cancers (8,9). Sometimes, increases in the levels of the protein encoded by p53 was found to be for increasing stabilization for different proteins, post-translationally, such as heat-shock proteins (10,11,14). This study was focused on the overexpression of the p53 gene in samples from tonsillitis tissues as benign lymphadenitis compared with adjacent normal tissue samples, and the results showed that the P53GE was slightly higher but not significant, 2.5-fold change and  $p > 0.05$ , than that in normal tissues. It has been shown that p53 could be detected relying on the p53 protein-other protein stabilization process (15). Some increases of the expression of p53 were detected in some patients that might have been due to upper respiratory tract viral infection such as human herpesvirus 8 and human papilloma viruses (16). It has been also demonstrated that there is negative regulation of NF- $\kappa$ B and the p53. Many of the studies indicate that there are changes of histopathological features that occur associated with tonsillitis-like conditions. This agrees with (17,18) who detected the same histopathological changes recorded in the current report such as necrosis and hyperplasia. These results match up with (19) who found that lymphoid follicles were affected by hyperplasia and hypertrophy. Microhemorrhages, hematic extravasations, and collagen fiber aggregation were recognized as this agrees with (20) who detected using the histological diagnosis that the conditions were

chronic tonsillitis at 16.6%, follicular tonsillitis at 38.3%, chronic supportive tonsillitis at 16.6%, lymphoid hyperplasia at 30.0%, and lymphoma at 1.0%. In conclusion, there is no activation of the p53 expression levels in the affected tonsils during tonsillitis. P53 gene expression was slightly higher but not significant than that in normal tissues that might have been due to upper respiratory tract viral infection.

#### REFERENCES

- Isaacson G, Parikh T. Developmental anatomy of the tonsil and its implications for intracapsular tonsillectomy. *Int J Pediatr Otorhinolaryngol* [Internet]. 2008 Jan [cited 2018 Oct 11];72(1):89–96. Available from: <http://linkinghub.elsevier.com/retrieve/pii/S0165587607004478>
- Klug TE, Rusan M, Fursted K, Ovesen T. Peritonsillar Abscess. *Otolaryngol Neck Surg* [Internet]. 2016 Aug 22 [cited 2018 Oct 11];155(2):199–207. Available from: <http://www.ncbi.nlm.nih.gov/pubmed/27026737>
- Windfuhr JP, Toepfner N, Steffen G, Waldfahrer F, Berner R. Clinical practice guideline: tonsillitis I. Diagnostics and nonsurgical management. *Eur Arch Otorhinolaryngol* [Internet]. 2016 Apr 11 [cited 2018 Oct 11];273(4):973–87. Available from: <http://link.springer.com/10.1007/s00405-015-3872-6>
- Ferri FF. Ferri's clinical advisor 2016 : 5 books in 1.
- Lang F. *Encyclopedia of molecular mechanisms of disease*. Springer; 2008.
- Jones R. *Oxford textbook of primary medical care*. Oxford University Press; 2004.
- Zhou Y, Ho WS. Combination of liquiritin, isoliquiritin and isoliquirigenin induce apoptotic cell death through upregulating p53 and p21 in the A549 non-small cell lung cancer cells. *Oncol Rep* [Internet]. 2014 Jan [cited 2018 Oct 11];31(1):298–304. Available from: <https://www.spandidos-publications.com/10.3892/or.2013.2849>
- Formigari A, Gregianin E, Irato P. The effect of zinc and the role of p53 in copper-induced cellular stress responses. *J Appl Toxicol* [Internet]. 2013 Jul [cited 2018 Oct 11];33(7):527–36. Available from: <http://doi.wiley.com/10.1002/jat.2854>
- May P, May E. Twenty years of p53 research: structural and functional aspects of the p53 protein. *Oncogene* [Internet]. 1999 Dec 13 [cited 2018 Oct 11];18(53):7621–36. Available from: <http://www.nature.com/articles/1203285>
- Finlay CA, Hinds PW, Tan TH, Elyahu D, Oren M, Levine AJ. Activating mutations for transformation by p53 produce a gene product that forms an hsc70-p53 complex with an altered half-life. *Mol Cell Biol* [Internet]. 1988 Feb [cited 2018 Oct 11];8(2):531–9. Available from: <http://www.ncbi.nlm.nih.gov/pubmed/2832726>
- Lane DP, Benichou S. p53: oncogene or anti-oncogene? *Genes Dev* [Internet]. 1990 Jan [cited 2018 Oct 11];4(1):1–8. Available from: <http://www.ncbi.nlm.nih.gov/pubmed/2137806>
- Livak KJ, Schmittgen TD. Analysis of Relative Gene Expression Data Using Real-Time Quantitative PCR and the 2- $\Delta\Delta$ CT Method. *Methods* [Internet]. 2001 Dec [cited 2018 Sep 12];25(4):402–8. Available from: <http://www.ncbi.nlm.nih.gov/pubmed/11846609>
- Kimura M, Tohya K, Tabata T. Phylogenetic and ultrastructural properties of the primitive tonsils of laboratory suncuses. *Adv Otorhinolaryngol* [Internet]. 1992 [cited 2018 Oct 11];47:21–7. Available from: <http://www.ncbi.nlm.nih.gov/pubmed/1456136>
- Cheah PL, Looi LM. p53: an overview of over two decades of study. *Malays J Pathol* [Internet]. 2001 Jun [cited 2018 Oct 11];23(1):9–16. Available from: <http://www.ncbi.nlm.nih.gov/pubmed/16329542>
- Villuendas R, Piris MA, Orradre JL, Mollejo M, Algara P, Sanchez L, et al. P53 protein expression in lymphomas and reactive lymphoid tissue. *J Pathol* [Internet]. 1992 Mar [cited 2018 Oct 11];166(3):235–41. Available from: <http://www.ncbi.nlm.nih.gov/pubmed/1381424>
- Yeo-Teh NSL, Ito Y, Jha S. High-Risk Human Papillomaviral Oncogenes E6 and E7 Target Key Cellular Pathways to Achieve Oncogenesis. *Int J Mol Sci* [Internet]. 2018 Jun 8 [cited 2018 Oct 11];19(6):1706. Available from: <http://www.mdpi.com/1422-0067/19/6/1706>
- Gudkov A V, Gurova K V, Komarova EA. Inflammation and p53: A Tale of Two Stresses. *Genes Cancer* [Internet]. 2011 Apr 1 [cited 2018 Oct 11];2(4):503–16. Available from: <http://gan.sagepub.com/lookup/doi/10.1177/1947601911409747>
- Erman A, Wabitsch M, Goodyer CG. Human growth hormone receptor (GHR) expression in obesity: II. Regulation of the human GHR gene by obesity-related factors. *Int J Obes* [Internet]. 2011 Dec 8 [cited 2018 Oct 11];35(12):1520–9. Available from: <http://www.ncbi.nlm.nih.gov/pubmed/21386799>
- Koycu A, Aydin E, Tulgar Kinik S. Changes in body composition and growth pattern after adenotonsillectomy in prepubertal children. *Int J Pediatr Otorhinolaryngol* [Internet]. 2016 Feb [cited 2018 Oct 11];81:46–50. Available from: <https://linkinghub.elsevier.com/retrieve/pii/S0165587615006254>
- Grace A, Veitch D, Ryan R, Barnes N, Coles T. Recurrent tonsillitis and growth in children. *Int J Pediatr Otorhinolaryngol* [Internet]. 1988 Nov [cited 2018 Oct 11];16(2):91–3. Available from: <http://www.ncbi.nlm.nih.gov/pubmed/3209364>